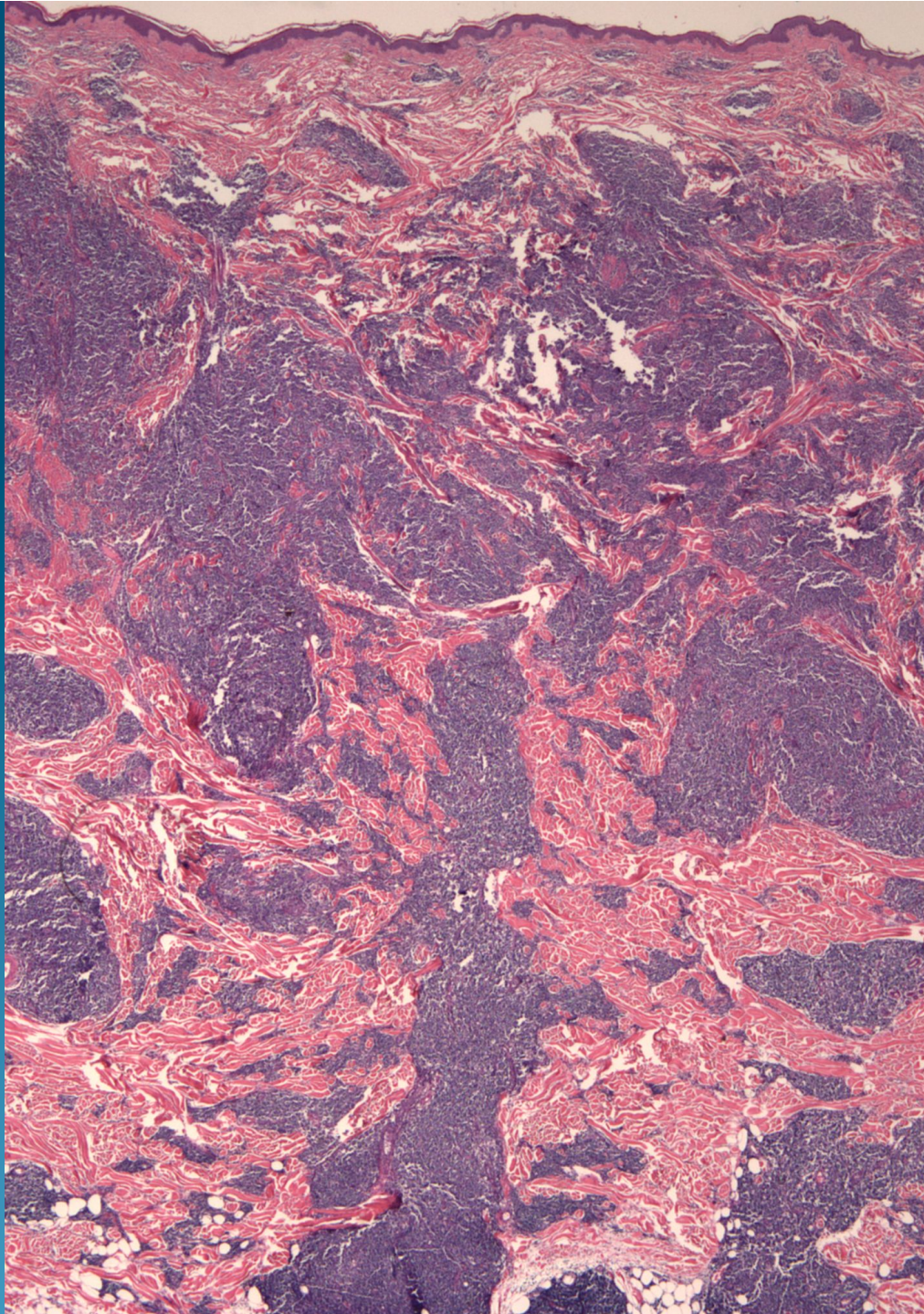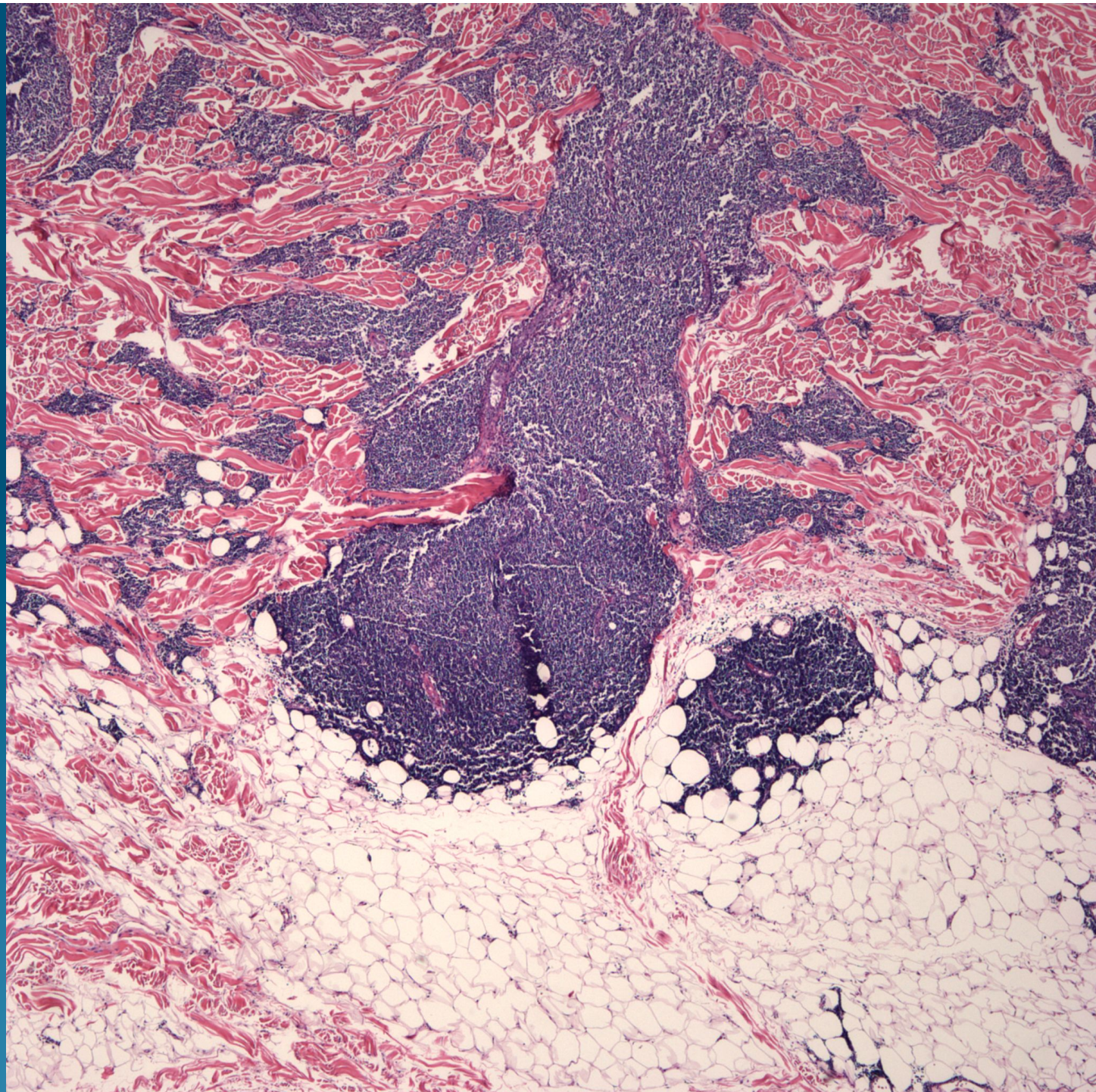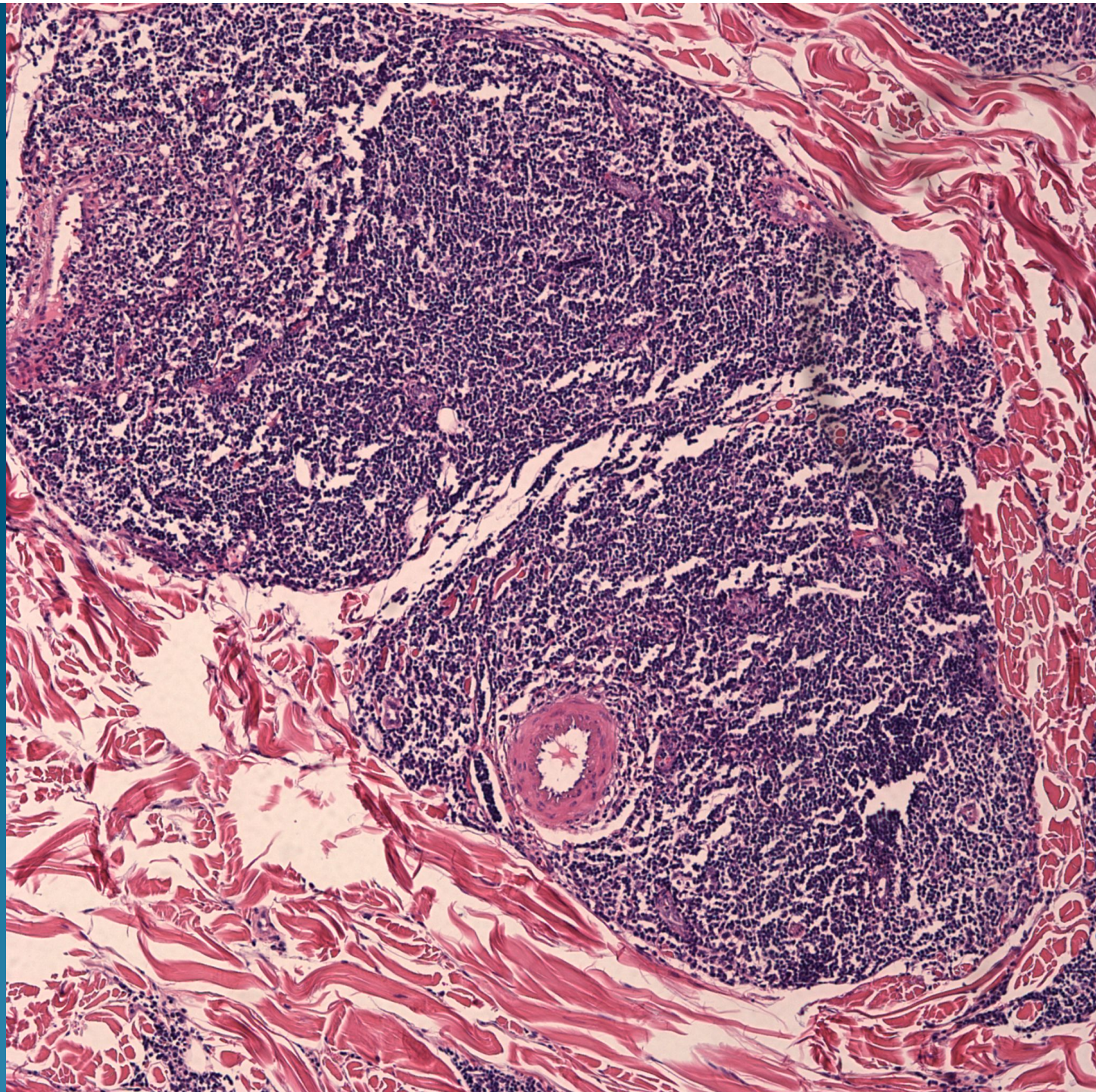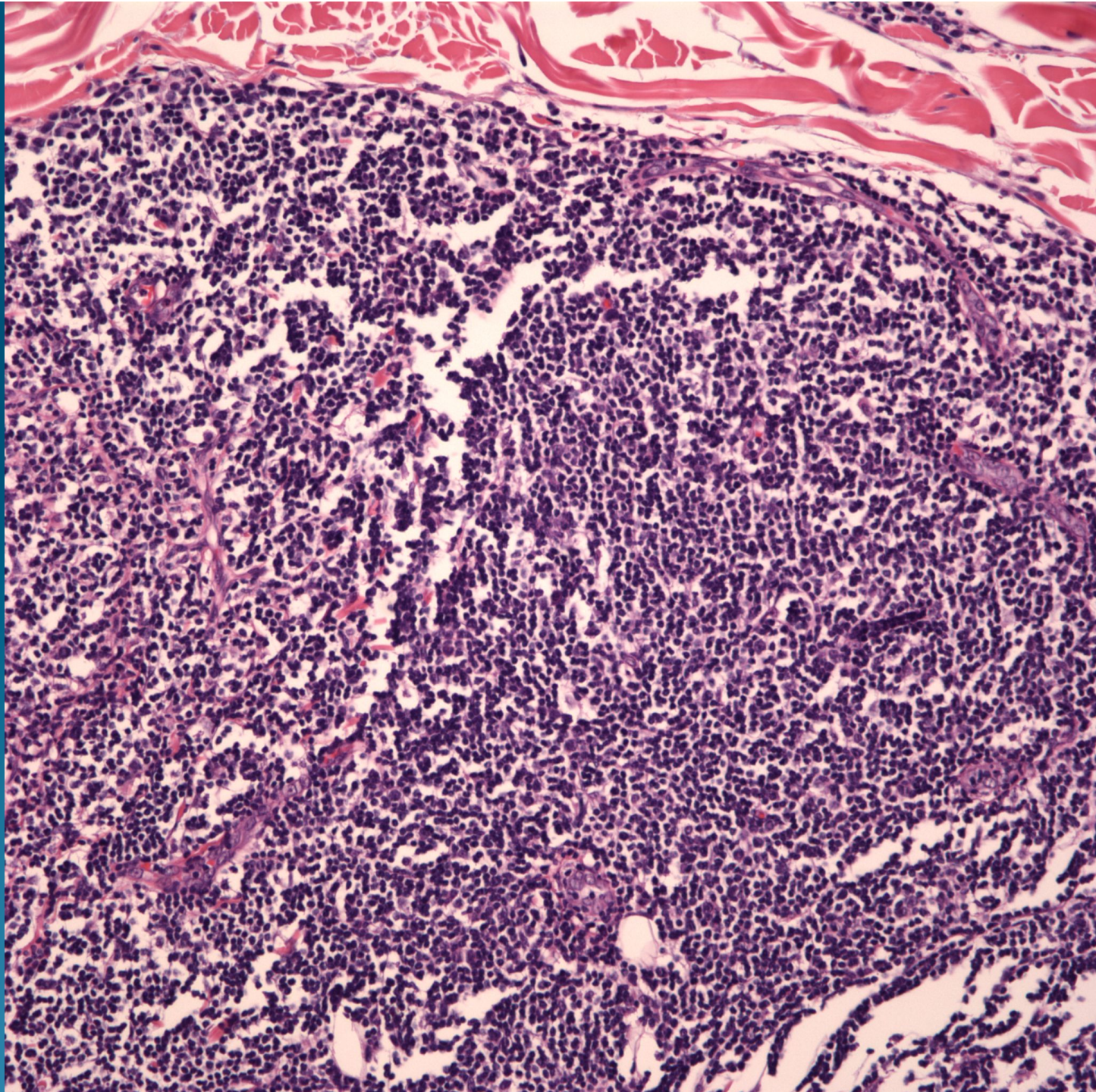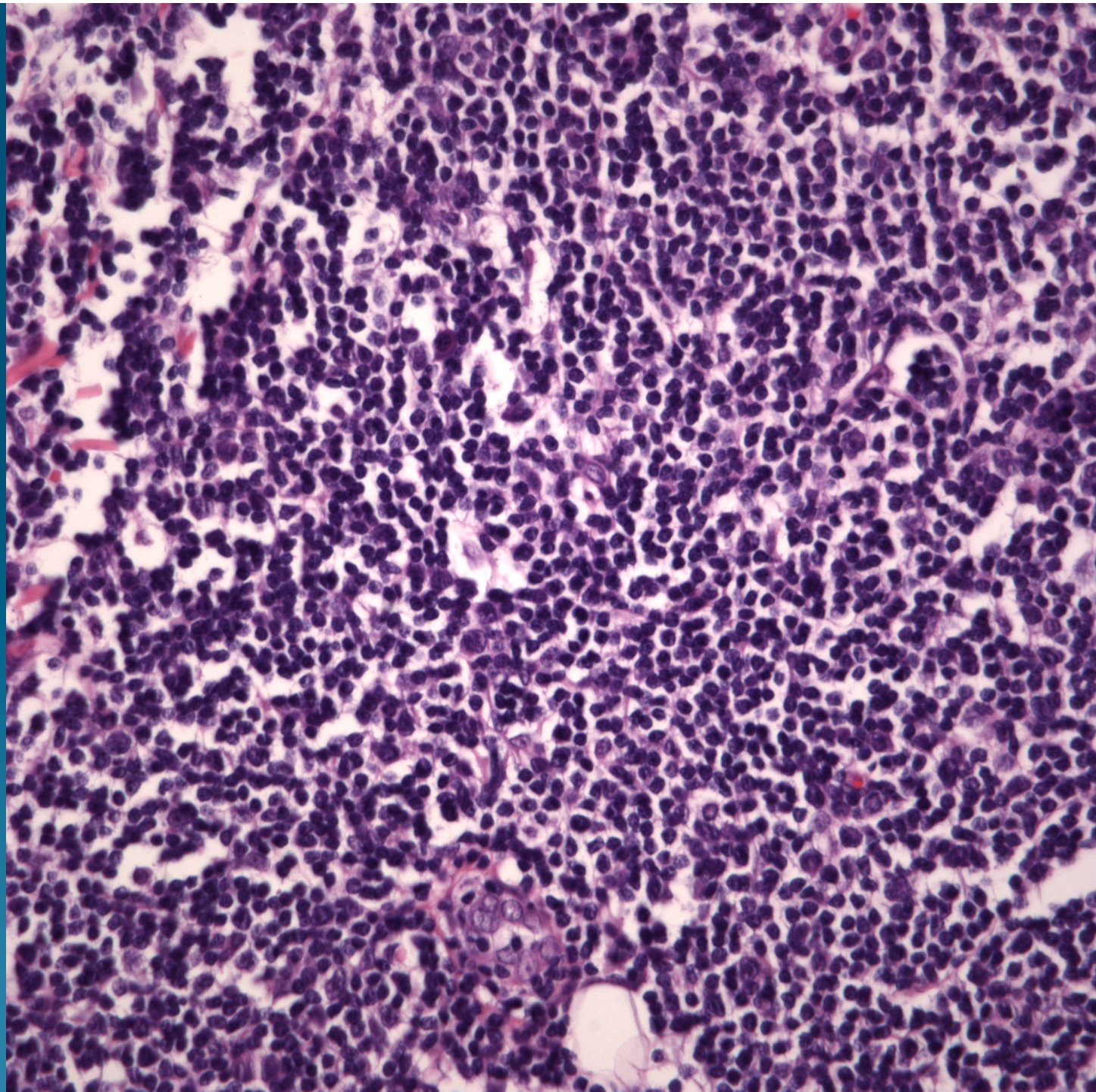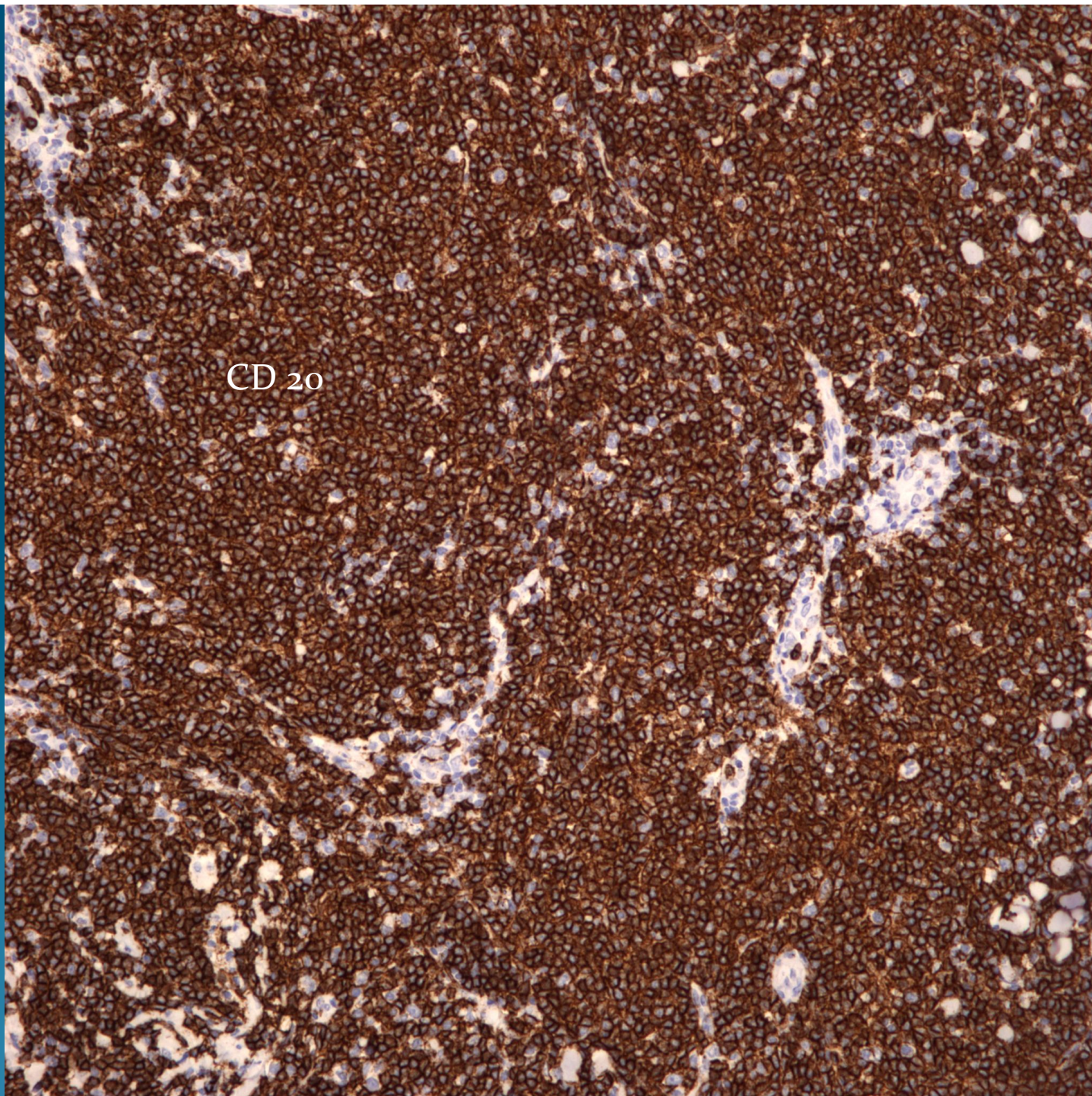




CD 20





# Cutaneous B-cell Lymphoma

## Marginal Zone Type

Grenz zone

Bottom heavy  
infiltrate

Small lymphocytes  
With germinal  
centers

